

The first ovarian tissue transplant between monozygotic twin sisters discordant for ovarian function in Latin America

Carlos G. Almodin¹, Paula M. Almodin¹, Moacir R. M. Radaelli^{1,2}, Vania C. Minguetti-Câmara¹, Alvaro P. Ceschin³, Rodrigo C. Ribeiro⁴

¹Materbaby – Reprodução Humana e Genética, Maringá/PR, Brazil

²Departamento de Cirurgia, Santa Casa de São Paulo, Escola de Ciências Médicas, São Paulo/SP, Brazil

³Feliccita – Instituto de Fertilidade, Curitiba/PR, Brazil

⁴Cegonha Medicina Reprodutiva, Belo Horizonte/MG, Brazil

ABSTRACT

Ovarian tissue transplant is an alternative to the cryopreservation of oocytes and embryos for the recovery of fertility and natural hormonal activity. The objective of this paper is to report on the first fresh ovarian tissue transplant between monozygotic twin sisters discordant for ovarian function, using the subcortical implant technique of ovarian tissue fragments, to take place in Latin America. A strip representing approximately a quarter of the cortical tissue was removed from the right ovary of the donor sister, cleaned, cut into small fragments and sent to adjacent room, where the receptor sister was concomitantly being prepared to receive the tissue graft. The ovarian fragments were placed under the cortical tissue onto a vascularized bed of the right ovary of the receptor sister. From 90 days postoperatively, the menstrual cycles of the receptor patient became regular with increased flow and longer periods, demonstrating normal hormonal activity and improved endometrial development.

Attempts at spontaneous pregnancy, and the recovery of an oocyte followed by fertilization have not yet been successful. However, the ovarian tissue transplant between monozygotic sisters reported here clearly highlights the potential of the technique as a therapeutic option for the preservation of fertility.

Keywords: Ovary, transplant, fertility.

INTRODUCTION

Ovarian tissue transplant is an alternative that have been diligently studied in the last 10 years for the recovery of fertility and natural hormonal activity (Donnez *et al.*, 2004). This procedure provides an option to the cryopreservation of oocytes and embryos for post-pubescent women, and may be the only option for pre-pubescent women (Silber & Gosden, 2004).

Several animal studies have already reported on the successful ovarian transplant for the recovery of fertility and natural hormonal levels (Parrott, 1960; Gosden & Aubard, 1996; Nugent *et al.*, 1997; Gunasena *et al.*, 1997; Candy *et al.*, 2000; Sonmezer & Oktay, 2004, Almodin *et al.*, 2004a,b). Due to this success, ovarian transplantation has emerged as a therapeutic option for the preservation of fertility in women surviving gonadotoxic treatments and patients with premature ovarian failure. In human beings, ovarian transplant has a recent history, with the first frozen/thawed ovarian tissue transplant being performed in 2004 (Donnez *et al.*, 2004), and the first fresh ovarian tissue transplant taking place between monozygotic twins discordant for premature ovarian failure in 2005 (Silber *et al.*, 2005).

Different techniques for the transplantation of ovarian tissue have already been described. Almodin and coworkers described the implant of frozen/thawed fragments of

ovarian tissue with the subcortical sowing of germinative tissue into an irradiated ovary both in sheep (Almodin *et al.*, 2004a) and rabbits (Almodin *et al.*, 2004b) with successful results. Another group led by Silber, reported on an implant technique by suturing ovarian tissue strips over the receptor ovary (Silber *et al.*, 2005), and the microsurgical transplantation of an intact ovary (Silber *et al.*, 2008) with the recovery of fertility in women.

The objective of this paper is to report on the first fresh ovarian tissue transplant between monozygotic twin sisters discordant for ovarian function, using the subcortical implant technique of ovarian tissue fragments, to take place in Latin America.

CASE PRESENTATION

Monozygotic, monozygotic twin sisters, aged 31 years, both married, were assessed for the resolution of a discordant premature ovarian failure condition. One of the sisters, presented normal ovarian function, with adequate menstrual cycle, without any symptoms of menopause, no intention to be pregnant at the moment of the consultation, and had been using contraceptives for the previous 5 years. In contrast, the other sister had developed idiopathic secondary amenorrhea at the age of 19, when she also presented symptoms typical of menopause such as heat, hot flushes, and headaches. At the time of the consultation, she had been in amenorrhea for 12 years uninterruptedly, and presented persistent high levels (160 mIU/ml) of follicle stimulating hormone (FSH). During the physical examination, no genital alterations were observed, and her female secondary sexual characteristics were considered normal. Menarche took place at the age of 12, and female internal genitalia showed no abnormalities. She had never been through any type of in vitro fertilization treatment previously.

The patient was informed on her options to reach gestation, such as oocyte donation from an anonymous donor, which she declined. In Brazil, directed donation of oocytes (between sisters) and, therefore, not anonymous, is not permitted. Thus, the simple donation of oocytes from one sister to another is forbidden by Brazilian law, and was not an alternative in this case. Albeit experimental, the orthotopic transplant of ovarian tissue from one sister to another was suggested, which both sisters considered an acceptable option.

The donor sister performed laboratory (FSH and Anti mullerian) and imaging (ovarian ultrasound with the counting of antral follicles) exams, which demonstrated normal ovarian reserve. Medical history assessment demonstrated that she was also physically fit. During her psychological assessment, she was thoroughly informed on the rationale and procedures involved in inter vivo ovarian tissue donation. She confirmed to fully understand the implications of the option, and declared

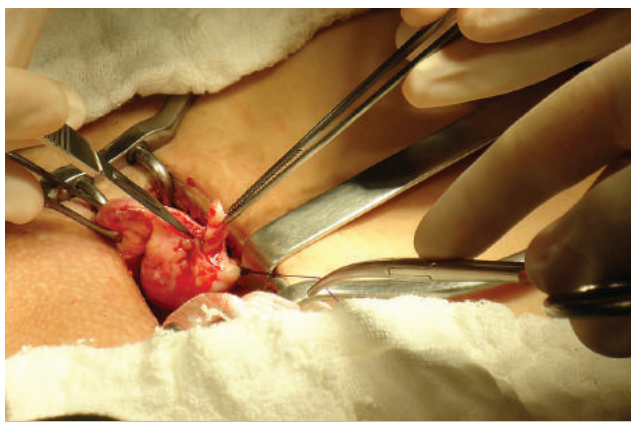


Figure 1. A strip representing approximately a quarter of the right ovary cortical tissue being removed from the donor sister.

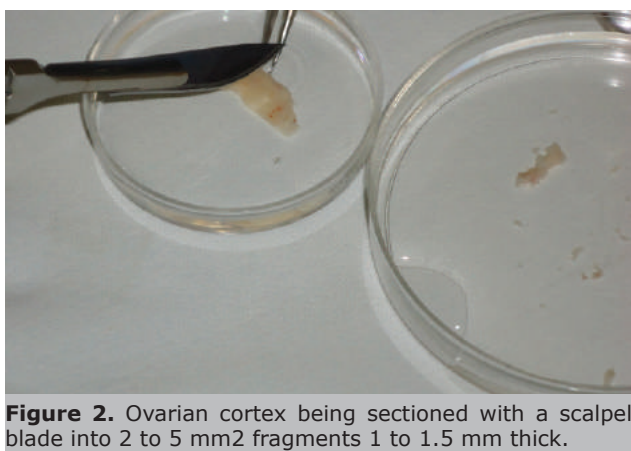


Figure 2. Ovarian cortex being sectioned with a scalpel blade into 2 to 5 mm² fragments 1 to 1.5 mm thick.

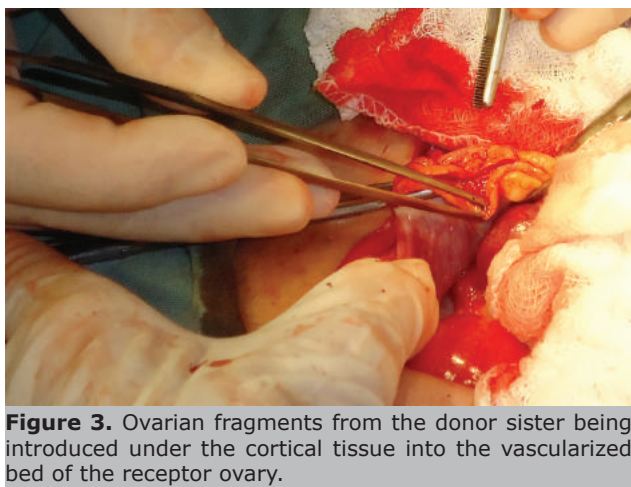


Figure 3. Ovarian fragments from the donor sister being introduced under the cortical tissue into the vascularized bed of the receptor ovary.

her intention to donor part of her ovary to her sister. All members of the family were then informed on their decision. Both husbands were fully informed on the procedure, after which they also agreed with the donation option. The receptor sister husband was then assessed and demonstrated to possess normal fertility levels.

Preoperative conduct

The surgery was duly approved by the Institutional Review Board of Materbaby – Reprodução Humana e Genética, Maringá, Brazil. After an informed consent form had been signed by the sisters and their respective husbands,

preparations for the fresh orthotopic ovarian tissue transplantation was initiated.

In order to ensure no cross-contamination between patients, both sisters were carefully investigated concerning the presence of possible previous transmittable diseases. Tests for hepatitis B and C, syphilis, HIV and HTLV were shown to be negative for both patients. Neither of them had been making use of any kind of medication 30 days previously to the surgical procedure. Before the transplant, a comprehensive assessment of the receptor sister condition was performed, which demonstrated FSH levels at 169 mIU/ml and estradiol levels at 7.31 pg/dl, confirming ovarian failure.

Surgical procedure

The donor sister was submitted to partial right oophorectomy on July 27th 2012. Under spinal anesthesia, a mini Pfannenstiel incision 5 cm long was performed, followed by the removal of a strip representing approximately a quarter of the right ovary cortical tissue (Figure 1).

The removed ovarian tissue was conditioned in buffer solution (Dulbecco's phosphate buffer, Ingamed, Brazil), rinsed for the removal of excess blood, and kept over crushed ice at a temperature of 4°C. Residual medullary areas were dissected and the ovarian cortex sectioned with a scalpel blade into 2 to 5 mm² fragments 1 to 1.5 mm thick (Figure 2), and sent to the adjacent room, where the receptor sister was being simultaneously prepared. Ovarian tissue preparation lasted for approximately 5 min. Four fragments of ovarian tissue from the donor sister were reserved: one fragment was sent to histological assessment, and the other three fragments were cryopreserved (Vitri-Inga, IngaMed, Maringá, Brazil) with the vitrification protocol described by Almodin *et al.* (2010). Then local hemostasis was conducted and the ovarian cortical tissue was sutured, followed by the suture of the patient's aponeurosis and skin.

The receptor sister, in the adjacent room, was synchronically submitted to a mini Pfannenstiel incision 5 cm long, with the right ovary being positioned in such way as to facilitate its handling. No follicle was observed on the receptor ovary, which was much reduced in size. No ovarian tissue was removed from the receptor sister. An incision of the cortical tissue was conducted with blunt dissection to plan, so that the presence of medullary vascularization was visible, to fabricate a bed to host the transplanted ovarian tissue fragments. After preparing the bed, to ensure proper irrigation of the tissue graft, rigorous hemostasis control was conducted to prevent bruising. A bipolar electro cautery was carefully used for the procedure. The ovarian fragments from the donor sister were introduced under the cortical tissue into the vascularized bed, where they were irrigated by soaking (Figure 3). After positioning the fragments subcortically, the cortical tissue was sutured over the fragments with a separated 5.0 monocryl thread suture, keeping the fragments fixed in contact with the vascularized medullary tissue.

Postoperative follow-up

The postoperative follow-up was performed by analyzing clinical parameters (menstrual cycle and symptoms) and complementary exams of the receptor patient. Control ultrasound (US) was conducted for the observation of bruises in the transplant area in the first and second days postoperatively. From 90 days postoperatively, US was performed monthly, together with laboratory exams for FSH, LH and estradiol levels.

Outcomes

Both patients had a calm uneventful postoperative period, and were released from hospital 24 h after the sur-

Table 1. Hormonal levels before and after the ovarian transplant.

Day	FSH	Estradiol
Before Transplant		
1	169	7.31
After Transplant		
98	27.3	20
125	1 st period	
180	12.5	
223	10.2	36
261	19.1	
285	9.7	
422	10.3	35.4

gery.

During the abdominal US conducted on the first postoperative day, the receptor ovary was in very good conditions without bruises. The anatomic-pathological exam of the ovarian fragment harvested from the donor sister indicated that the ovary was normal, with the presence of primordial follicles.

Clinically, the receptor patient presented a significant improvement of her menopause symptoms after a period of 70 days. At 90 days postoperatively, laboratory and US exams were started to assess ovary response to the transplant. At that moment, hormonal levels of the patient were consistent with normal ovarian activity, with decreased FSH levels and increased estradiol levels (Table 1).

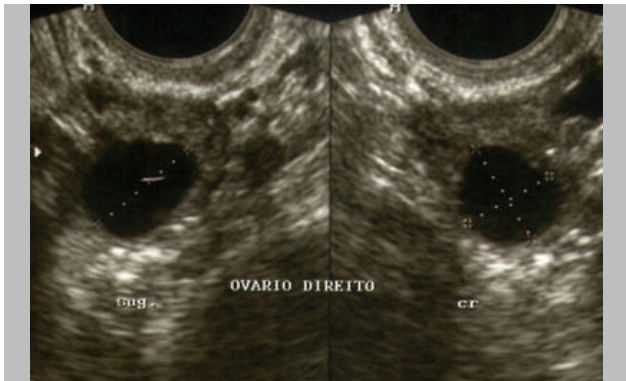


Figure 4. Pre ovulatory follicle with 18 mm in the transplanted right ovary.

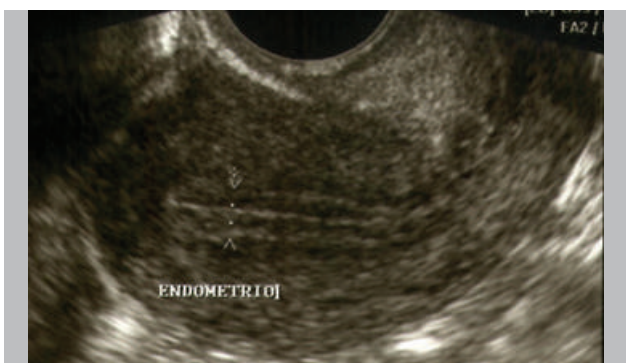

Figure 5. Trilaminar endometrium with 9 mm thick.

At 4 months postoperatively, she started to present normal menstrual cycles. At 6 months postoperatively, she presented FSH levels at 12.5, menstrual cycles with regular intervals of 28 days, and normal menstrual flow. At that moment, ovulatory control and programmed intercourse were attempted without success in obtaining pregnancy.

The 18-month US assessment demonstrated the presence of follicles in the right ovary and trilaminar endometrium (Figures 4 and 5). Follicles with 18 mm in diameter were observed around the middle of the cycle. As the attempts to spontaneous pregnancy in previous ovulatory cycles were not successful, a new attempt, this time with follicle aspiration and fertilization, was conducted in one of the cycles. However, as there was no adequate embryo cleavage, it was decided not to proceed with the embryo transfer. Although the patient has shown progressive improvement in her hormonal profile, she has not been able to become pregnant as yet.

DISCUSSION

This paper reports on the first orthotopic ovarian tissue transplant *inter vivo* to take place in Latin America between monozygotic twin sisters discordant for premature ovarian failure.

In agreement with the findings of Silber & Gosden (2007), monozygotic and monoamniotic twin pregnancy is a rare event, occurring in just 1 to 3 % of the cases (Su, 2002). It has been suggested that this condition is perhaps associated with premature ovarian failure between twin sisters, possibly secondary to a delay in the embryonic division, which may cause a delay in the adequate position of the ovarian tissue and lead to epigenetic changes that regulate oogenesis (Weksberg *et al.*, 2002).

The receptor patient in this report had been in amenorrhea since she was 19 years and presented high FSH levels, which dropped only after the ovarian transplant. Previous studies (Silber & Gosden, 2005) observed that hormonal levels tended to normalize from 90 days postoperatively. Thus, in this study, monthly hormonal level assessments were initiated from the third month postoperatively. Then, ovarian function recovery was evident with continuous and steady decrease in FSH levels and increased estradiol levels. Menstrual cycles became regular with increased flow and longer periods, demonstrating normal hormonal activity and improved endometrial development. The presence of ovulatory cycles with attempts at spontaneous pregnancy, followed by the recovery of an oocyte and the attempted fertilization also demonstrated the presence of normal ovarian activity after the transplant. Ovarian transplantation between monozygotic twins discordant for premature ovarian failure has already been reported in the literature, with positive results with gestations and live births in women (Silber & Gosden, 2004; Silber *et al.*, 2005). However, the transplantation technique used in those works involved the transplant of strips of ovarian cortical tissue, which were sutured over the recipient ovary.

The first report of the technique used in the transplant procedure described here was conducted by Almodin *et al.* (2004a,b), in which small fragments of frozen/thawed cryopreserved cortical tissue were sowed under the cortical tissue of an irradiated ovary. The transplanted tissue was placed in direct contact with the ovarian medullary tissue, leading to the recovery of normal hormonal function and live birth in sheep (Almodin *et al.*, 2004a) and rabbits (Almodin *et al.*, 2004b). The option for the transplant in fragments was based on 3 basic elements: i) the success observed in previous studies performed in animals (Almodin *et al.*, 2004a,b) and humans (Donnez *et al.*, 2004), which presented good tissue colonization; ii) the technique is simple and requires short surgical time, especially when com-

pared with microsurgical vascular anastomosis techniques; and iii) the possibility of cryopreserving some of the fragments of the ovarian tissue for future use. It has been previously shown that the smaller the size of ovarian tissue fragments the better tissue and follicle recovery after cryopreservation and thawing (Ferreira *et al.*, 2008).

The most significant technical limitation during ovarian tissue transplant is the need for ovarian medullary vascularization in optimal conditions for the adequate irrigation of the transplanted tissue. This limitation is, however, present in any graft technique without vascular anastomosis, both in fragments and strips of ovarian tissue.

Although the receptor patient is still to get pregnant, the technique has proven to be successful in recovery normal ovary function. Therefore, it may be concluded that the ovarian tissue transplant between monozygotic sisters reported here, highlights the potential of the technique for wider use. The main applicability of this technique is for patients submitted to gonadotoxic treatments which are likely to result in compromised fertility.

In such patients, one of their ovaries could be removed before the life-saving treatment, the ovarian tissue cryopreserved, and transplanted in the remaining ovary after their recovery. Care, however, must always be exercised to ensure that malignant cells are not reintroduced in the patient.

Acknowledgement: The authors would like to thank Mr. Antonio Carlos Correa for his support with the English version of the manuscript.

CONFLICT OF INTERESTS

No conflict of interest have been declared.

Corresponding author:

Carlos Gilberto Almodin
Materbaby – Reprodução Humana e Genética
Av. XV de Novembro, 1232
Maringá/PR - Brazil
E-mail: almodin@materbaby.com.br

REFERENCES

Almodin CG, Minguetti-Câmara VC, Meister H, Ceschin AP, Kriger E, Ferreira JO. Recovery of natural fertility after grafting of cryopreserved germinative tissue in ewes subjected to radiotherapy. *Fertil Steril.* 2004a;81:160-4.

Almodin CG, Minguetti-Câmara VC, Meister H, Ferreira JO, Franco RL, Cavalcante AA, Radaelli MR, Bahls AS, Moron AF, Murta CG. Recovery of fertility after grafting of cryopreserved germinative tissue in female rabbits following radiotherapy. *Hum Reprod.* 2004b;19:1287-93.

Candy CJ, Wood MJ, Whittingham DG. Restoration of a nor-

mal reproductive lifespan after grafting of mouse ovaries. *Hum Reprod.* 2000;15:1300-4.

Donnez J, Dolmans MM, Demylle D, Jadoul P, Pirard C, Squifflet J, Martinez-Madrid B, van Langendonck A. Livebirth after orthotopic transplantation of cryopreserved ovarian tissue. *Lancet.* 2004;364:1405-10.

Ferreira ML, Bos-Mikich A, Frantz N, Rodrigues JL, Brunetto AL, Schwartzmann G. The effects of sample size on the outcome of ovarian tissue cryopreservation. *Reprod Domest Anim.* 2010;45:99-102.

Gosden RG, Aubard Y. Transplantation of ovarian and testicular tissues. Medical Intelligence Unit, R.G. Landes Co., Austin, Texas. 1996.

Gunasena KT, Villines TM, Critser ES, Critser JK. Live births after autologous transplant of cryopreserved mouse ovaries. *Hum Reprod.* 1997;12:101-6.

Nugent D, Meirou D, Brook PF, Aubard Y, Gosden RG. Transplantation in reproductive medicine: previous experience, present knowledge and future prospects. *Hum Reprod Update.* 1997;3:267-80.

Parrott DMV. The fertility of mice with orthotopic ovarian grafts derived from frozen tissue. *J Reprod Fertil.* 1960;1:230-41.

Silber SJ, Gosden RG. Ovarian transplantation in a series of monozygotic twins discordant for ovarian failure. *N Engl J Med.* 2007;356:1382-4.

Silber SJ, Lenahan KM, Levine DJ, Pineda JA, Gorman KS, Friez MJ, Crawford EC, Gosden RG. Ovarian transplantation between monozygotic twins discordant for premature ovarian failure. *N Engl J Med.* 2005;353:58-63.

Silber SJ, Grudzinskas G, Gosden RG. Successful pregnancy after microsurgical transplantation of an intact ovary. *N Engl J Med.* 2008;359:2617-8.

Sonmezer M, Oktay K. Fertility preservation in female patients. *Hum Reprod Update.* 2004;10:251-66.

Su LL. Monoamniotic twins: diagnosis and management. *Acta Obstet Gynecol Scand.* 2002;81:995-1000.

Weksberg R, Shuman C, Caluseriu O, Smith AC, Fei YL, Nishikawa J, Stockley TL, Best L, Chitayat D, Olney A, Ives E, Schneider A, Bestor TH, Li M, Sadowski P, Squire J. Discordant KCNQ1OT1 imprinting in sets of monozygotic twins discordant for Beckwith-Wiedemann syndrome. *Hum Mol Genet.* 2002;11:1317-25.